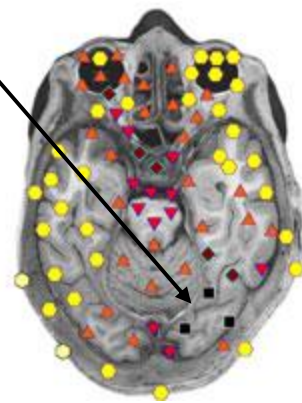
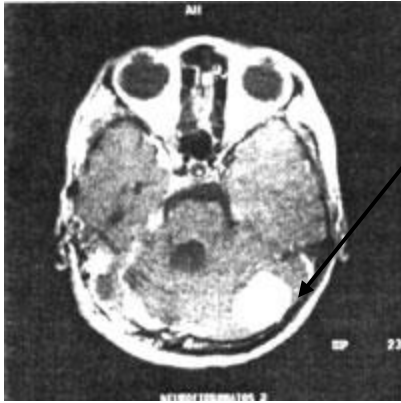
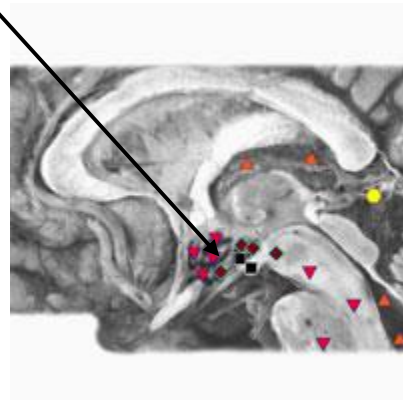
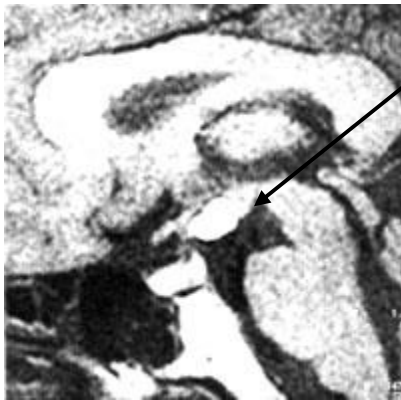


Direct Comparison of MRI and 9D-NLB-A

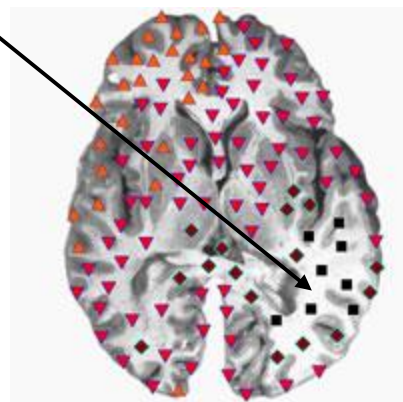
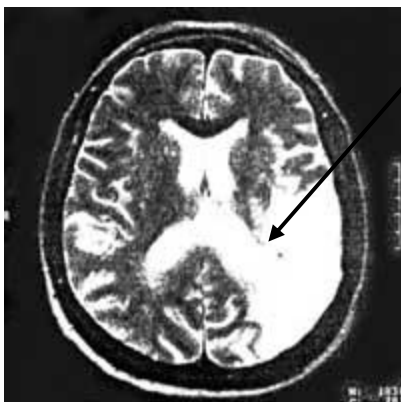57 years old. Neurofibromatosis.



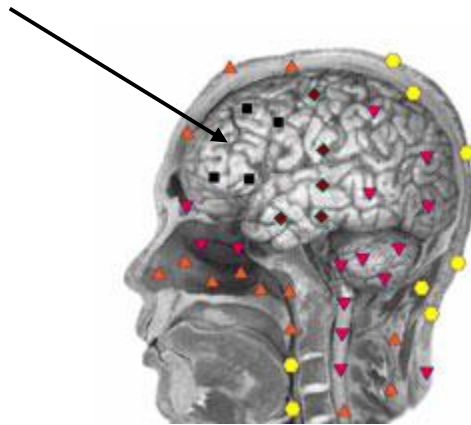
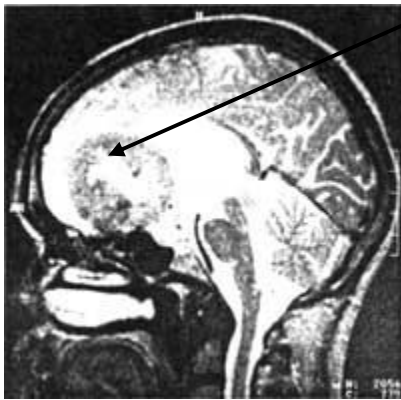
37 years old. Lipoma of the hypothalamus.



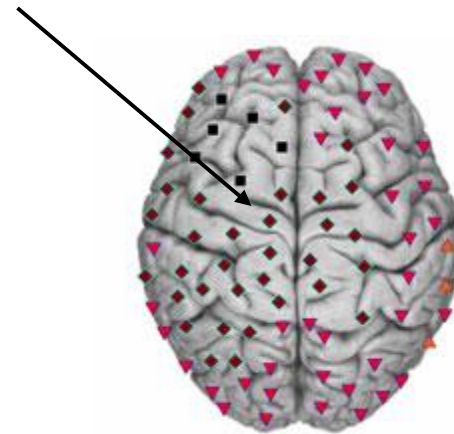
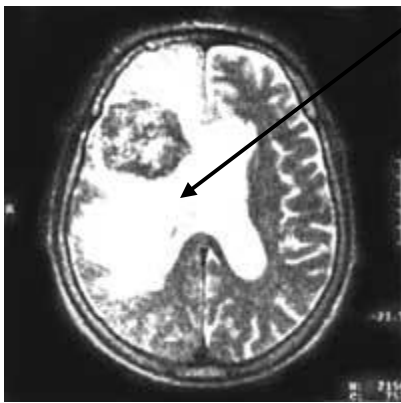43 years old. Acute ischemic stroke.



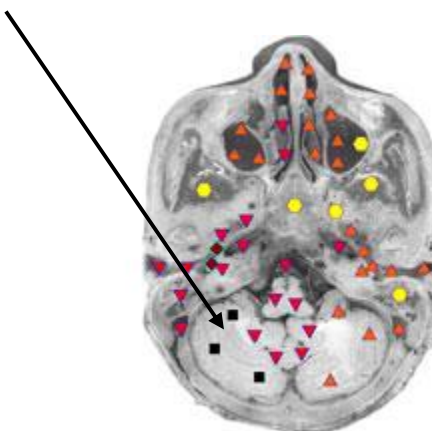
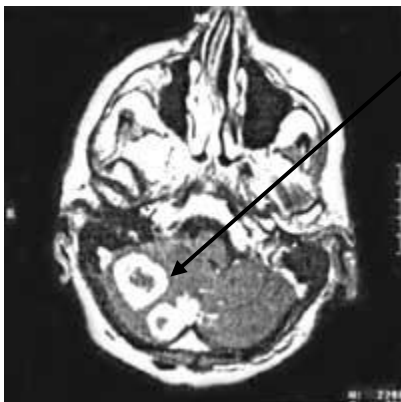38 years old. Subfrontalnaya meningioma.



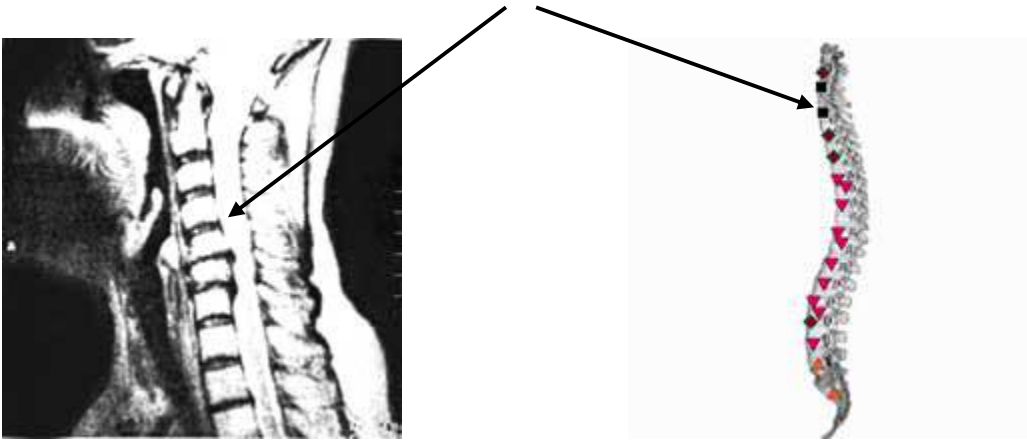
56 years old. Metastasis of lung cancer in the left frontal lobe.




62 years old. Renal adenocarcinoma metastases to the right hemisphere of the cerebellum.



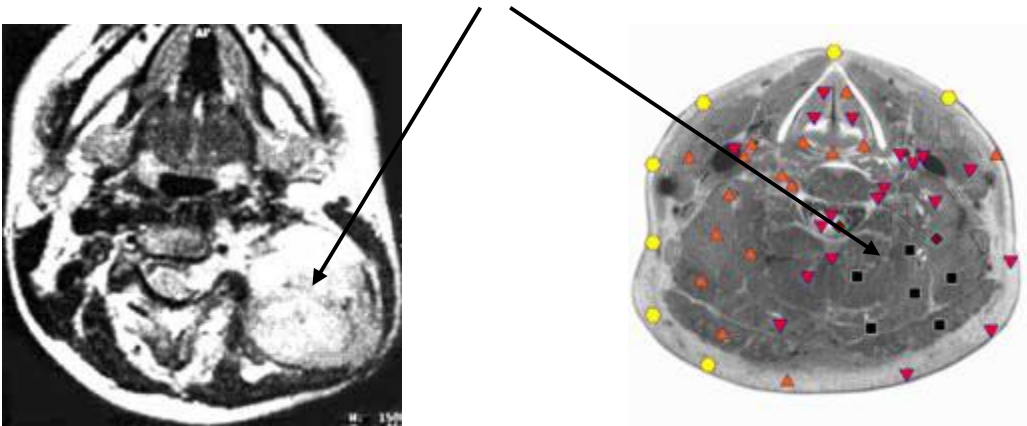
56 years old. Osteochondrosis of the cervical spine with a reduction in the height of the rear discs and hernias.



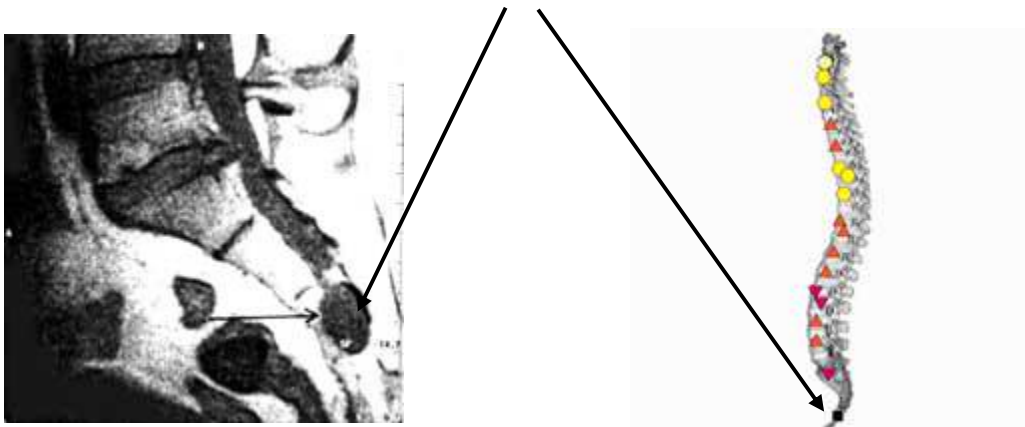
67 years old. Fibrosarcoma sacrum.



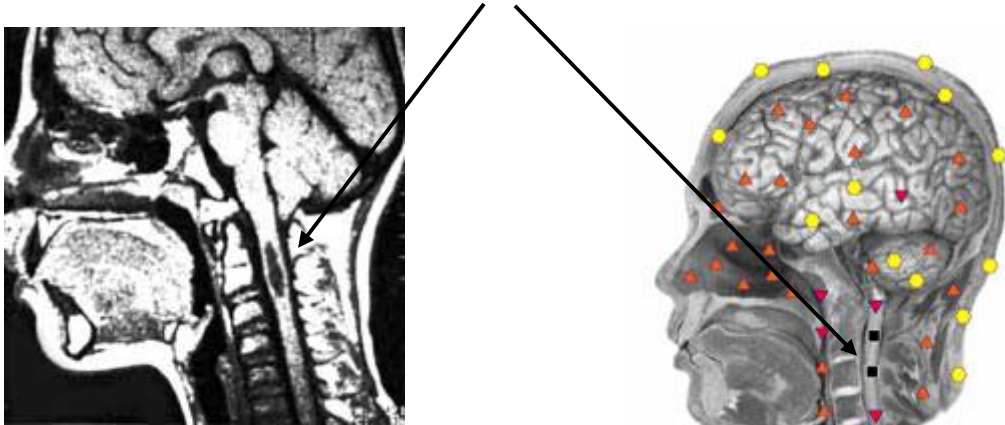
58 years old. Simpatoblastoma cervical localization.



58 years old. Simpatoblastoma cervical localization.



49 years old. Perineural arachnoid cysts.



58 years old Male with 3 Herniated Discs

